

Where a vital structure is injured — for example, the parotid duct — ligate it if injured on only one side; if injured on both sides, refer the patient on.

Facial injuries are a good example of the value of making a sound assessment and then using the telephone for advice. If the mandible is intact and the airway is clear, a repair can be done later; if the mandible is fractured and displaced posteriorly, it may obstruct the airway and will need to be pulled forward and wired.

When the oral cavity communicates with an antrum and food passes into the antral cavity, an obturator must be devised — refer for specialist attention.

Eyes

Wash the area out, cover with vaseline dressing and refer.

Ears

Heal badly. Debride and repair by closing skin if possible.

Lip

Debride and close the wound.

Neck

Any significant wound of the neck — refer on.

1. If there has been a laceration of the oesophagus, insert a naso-gastric tube.
2. If the trachea is perforated, but not bleeding, leave it alone.
3. If it is bubbling blood, insert an endo-tracheal tube in the hole and refer.
4. If major blood vessels are injured it is unlikely that the patient has reached hospital.

Chest

1. X-ray in all cases.
2. If there is subcutaneous emphysema, leave it alone (do not incise etc.)
3. If there is a sucking wound, debride and close with underwater seal drain;
4. If there is pneumothorax or haemo-pneumothorax, insert an underwater seal drain.
5. If there is haemo-pericardium, aspirate it.

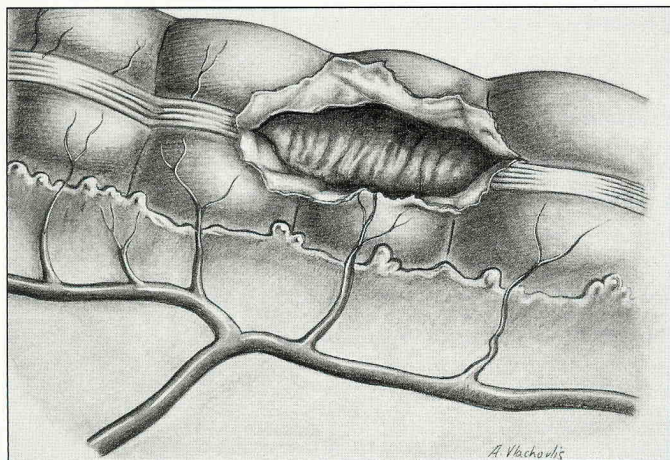


Figure 22a. An injury opening into the large bowel can be converted into a double stoma.

Abdomen

Abdomen and chest wounds will likely have occurred at the same time.

1. If the abdomen has been penetrated, explore it and inspect for internal damage. Proceed according to what you find.
2. Liver, stomach, and duodenum may all be injured by penetration from the posterior wall; examine the back carefully.
3. It is important not to miss a perforation of bowel — look for a haematoma on the surface of the bowel; you will have to mobilise the bowel to examine it carefully.
4. For perforated small bowel, over-sew small lesions, resect larger damaged areas, and anastomose the ends.
5. Perforated large bowel requires diversion after resection, with creation of a stoma.
6. If the caecum has been injured, do an ileostomy. It may be possible to bring a hole in the large bowel to the surface as a double stoma.
7. A retroperitoneal haematoma is a major source of infection. If it can be explored and drained and haemostasis established, do so; otherwise refer quickly.
8. One hole in the abdomen often means there is another hole. (Exit) Look and look. Be alert for abdomino-thoracic wounds where the entrance wound and the exit wounds are far apart. If a fragment has entered via the chest and lodged in the abdomen it may only become apparent when an acute abdomen develops.

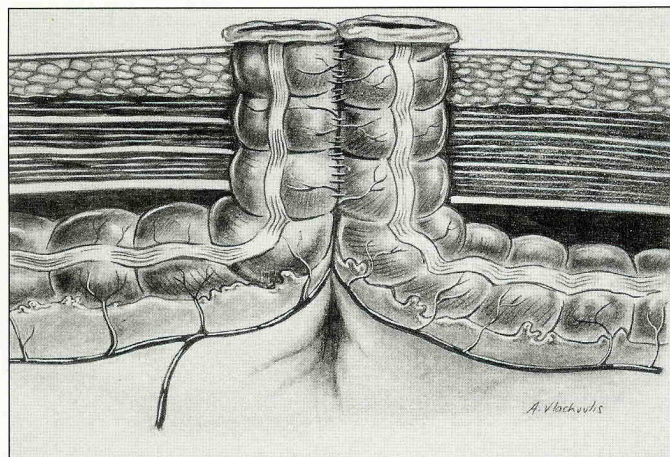


Figure 22b. A double stoma fashioned from perforation in the bowel wall.

Bladder

Repair and drain

Perineum

Do not neglect to examine carefully. Blast injuries from below may injure the perineum.

Vagina

Do not neglect to examine carefully.

Testis

Excise if a testis is badly damaged.

Retained Shrapnel

This will occur with a low-velocity wound (high velocity missiles penetrate right through). Remove it if it appears to be causing symptoms, if you can see it or feel it in the wound, or if it seems likely to cause complications. Most pieces of metal will not cause sepsis.

Any shrapnel in a joint must come out, any piece alongside a blood vessel must be removed; if it has passed through bowel it is probably contaminated and should be removed; if it has lodged in a disk space it should be removed.

AMPUTATION

There are three main situations to consider.

1. A traumatic amputation — part of the leg has already been removed by the explosion. Here the task is to debride, dress, and later re-fashion a stump.
2. Partial amputation, where the limb is hanging on by shreds of tissue but is non-viable. Amputation has to be completed. But skin on the limb which is being discarded may remain viable and can be preserved. Harvest the skin from that limb as a split skin graft, lay it out flat (pegged down) on wet saline gauze, roll it up, and store in the refrigerator for the later procedure to fashion a useful stump.
3. A badly mangled limb which will be dangerous to leave attached.

Indications for Amputation

THREE Ds

Amputation will be necessary if the limb shows evidence of being:

DEAD

- No perfusion because blood vessels destroyed
- No sensation because nerves destroyed

DANGEROUS

- Devitalised tissues make a perfect culture medium for bacteria

DAMNED NUISANCE

- So much muscle or bone has been lost that the limb will never function well

NO ADEQUATE PERFUSION

A major artery is damaged beyond repair, so that tissues it normally supplies with blood are no longer receiving adequate circulation.

1. Examine the tissues down the limb.

If there is no perfusion (warmth, capillary re-fill) and if the tissues of the peripheral part of the limb are clearly dead, amputation will be necessary.

2. If there is an uncertainty, first of all do a fasciotomy; and then WAIT — it may release pressure on remaining blood vessels and save the limb.

LOSS OF TISSUE

Consider each of:

SKIN	MUSCLE	MAJOR BLOOD VESSELS	MAJOR NERVES	BONE
------	--------	---------------------	--------------	------

If any THREE of these FIVE are damaged beyond repair, amputation will be necessary.

CRUSH INJURY

A crushed or mangled limb — one which has not just been penetrated by fragments, but mangled right through, MUST COME OFF.

THE BETTER LIMB

1. Do not focus entirely on the most badly damaged limb — also assess the less damaged limb.
2. Here you can afford to be more conservative if the damage is not so dangerous. If the foot still has feeling — WAIT. Shock may have dropped the blood pressure and perfusion may improve. Capillary filling and warmth in the foot gives best guidance to viability.
3. If there has been a penetrating wound but no obvious major bleeding, yet no pulse, consider performing a fasciotomy (see page 50) and exploring the major artery, where an intra-luminal stent may be possible.
4. If the area above the knee has been massively injured, there is a risk of thigh compartment syndrome. Look carefully for evidence of the muscle compartment being tense and hard. Pain will often be out of proportion to the swelling. If there is shock and low blood pressure the compartment may not become so very tense. If in any doubt incise the fascia.

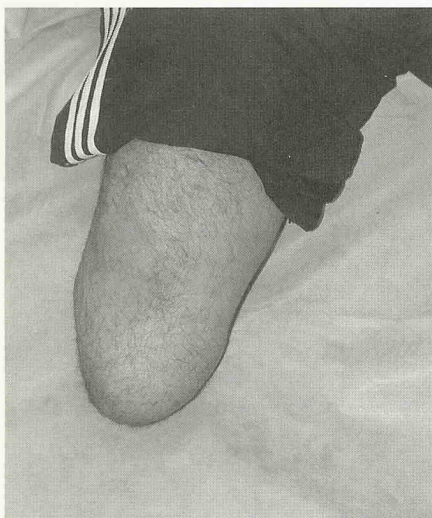


Figure 23. A smoothly tapered stump is easy to fit with a prosthesis.

In 156 cases of Pattern 1 Injury (stepping on a blast mine) 186 lower limb amputations were necessary (approximately 75% below knee, 25% above knee and a few of the foot only); in 41 Pattern 3 Injuries (handling a mine which explodes) there were 39 amputations (two-thirds of the hand only; one third of the forearm).

JUDGING THE LEVEL OF AMPUTATION

When mainly the foot has been injured and it is not viable, a good result would be an end-bearing limb at the level of the foot. There is no advantage in a long tibia if the narrow shaft is all that is left. A Symes operation is based on disarticulation at the heel and can be considered if the forefoot has been blown off. It needs sensation on the heel tissues, and a good blood supply — it is not an easy operation to perform; it needs to be done with skill so that the heel flap is preserved.

If you feel that such an operation may be possible, debride and refer to an expert surgeon.

Once the injury is such that amputation must be done above the level of the ankle you are dealing with a BELOW-KNEE AMPUTATION.

GUILLOTINE AMPUTATION AS A FIRST PROCEDURE

As an immediate procedure a “guillotine” amputation can be done at the level of viable tissue, and a below-knee amputation done more carefully a few days later.

“Guillotine” seems to imply cutting the limb straight across. This is not a good term, because skin below that level on the posterior side of the leg can often be preserved allowing a long flap which may look quite unsightly, but will be very useful later at the time of a careful below-knee procedure. Refer to it as an “Adequate Wound Excision.”

AMPUTATION TECHNIQUE

Principles

Traumatic amputation is not the same as an elective amputation. The level where the amputation can be done, the flaps which can be arranged and the placement of scars in relation to the stump are determined by the injury.

Improvisation with intelligent use of the available tissue is required.

The commonest problems with fitting a prosthesis are those due to a poorly shaped stump, not the length of the remaining limb.

- Don't decide on how you will shape the flaps at the first look; wait until the debridement is complete, and the wound has been re-visited.
- Preserve all the skin that looks as though it might survive. Some will die later, but you cannot afford to remove any skin which will survive.

- Save split skin from the surface of parts which have already been partially amputated, or where that part of the limb is to be discarded. Stretch the removed skin on a flat surface between two small boards and cut thin surface slices as for ordinary split skin grafts. It can be laid on sterile gauze, rolled up and stored for use later.
 - NEVER CLOSE UP the wound at the first procedure (even when "It looks so clean").
 - Keep any long flaps and fold them over the exposed bone — they will keep the bone moist.
 - Tack the flaps down with only two sutures — it will not look neat, but it must be able to drain.
1. Preserve the knee joint wherever possible.
 2. Lower limbs have "standard levels" for amputation if the injury allows some choice:

Syme amputation at the foot if the heel is totally uninjured;

Transtibial — about a patient hand's breadth below the tibial tubercle. Note that a shorter below-knee stump is much more use to the patient than one through the knee or a trans-femoral amputation;

A trans-femoral amputation seeks to preserve as much length as possible within the limits of cover by skin and soft tissue;

A through-the-knee can be done if there is adequate skin with sensation to cover it.

3. In upper limbs forget levels and preserve every piece of length possible.

If a patient must remain at the District Hospital, and there is no opportunity to refer on to a larger centre, it is best to be more radical in making an amputation higher, because there is more risk to the patient from leaving devitalised tissue in place. In a major centre, there will be better facilities and the surgeon can take a risk, then deal with it later.

Syme Amputation

When disarticulation of the talus and calcaneum bones is completed,

1. Cut the malleoli at the lower end of the tibia-fibula flush with the distal articular surface of the tibia.
2. If a prosthesis is to be fitted, additional tapering of the end of the tibia on both medial and lateral sides will assist fitting of the prosthesis.
3. If there is no expectation that a prosthesis will be fitted, cut the malleoli off straight across.