



ONE BULLET STORY: Nepal

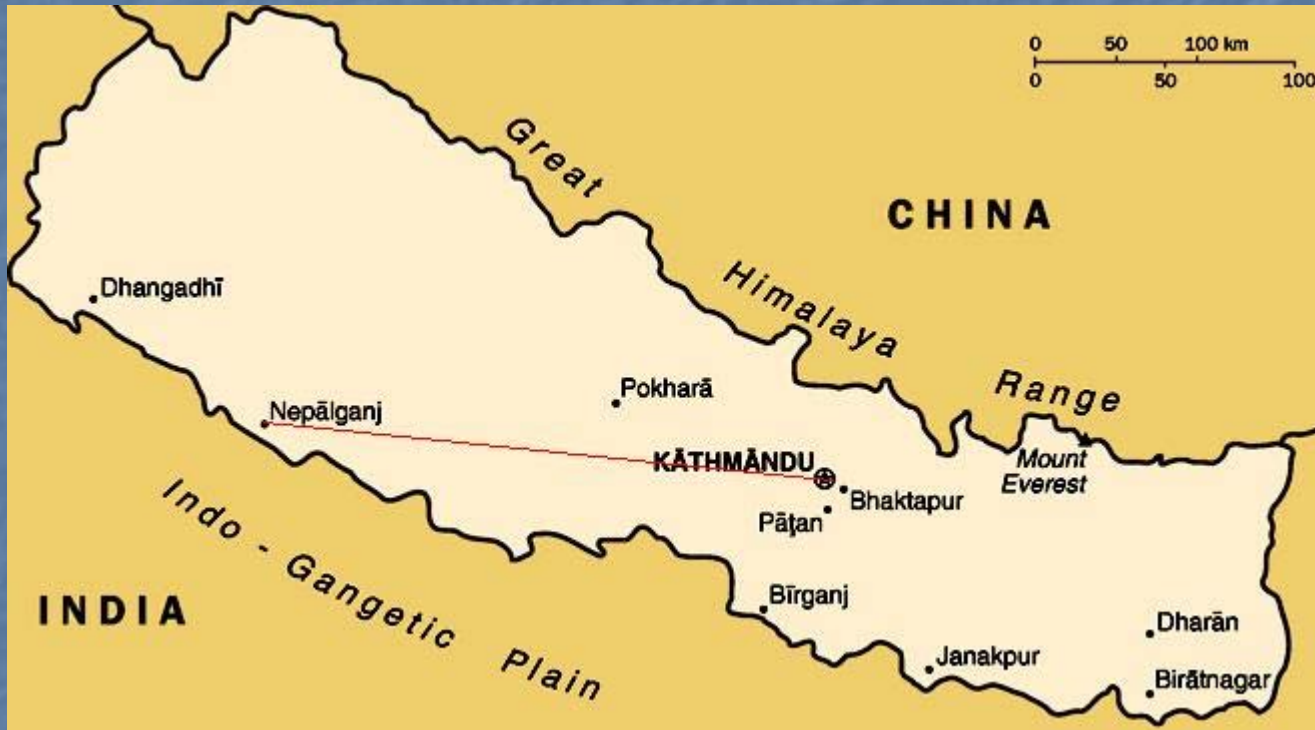
Anjan Khadka Kathmandu Medical College and Teaching Hospital (KMCTH)

Dinesh Dharel Institute of Medicine (IOM)

Surya Bhatta National Institute of Health Sciences (NIHS)

*“One Bullet Story” is a Project of
International Physicians for the Prevention of Nuclear War (IPPNW)*





HOW the STORY BEGINS.....

It was a very tense day for people in Nepalgunj, Nepal where riots were taking place....

The Bullet
Nepalgunj incident



A 15 year old school girl,
Manashi, had just returned from
school and was asking her mother
for some snacks.

While the mother started making food for her darling child, the girl was attracted by the noise outside.

She went to the verandah.

Amazed by the noise and smoke rising up to the sky, she stooped over the grill to see things more clearly, completely unaware of the pending danger...

Then....

Before she knew what happened, the innocent 15 year girl felt something pushing her head backwards and to the left.

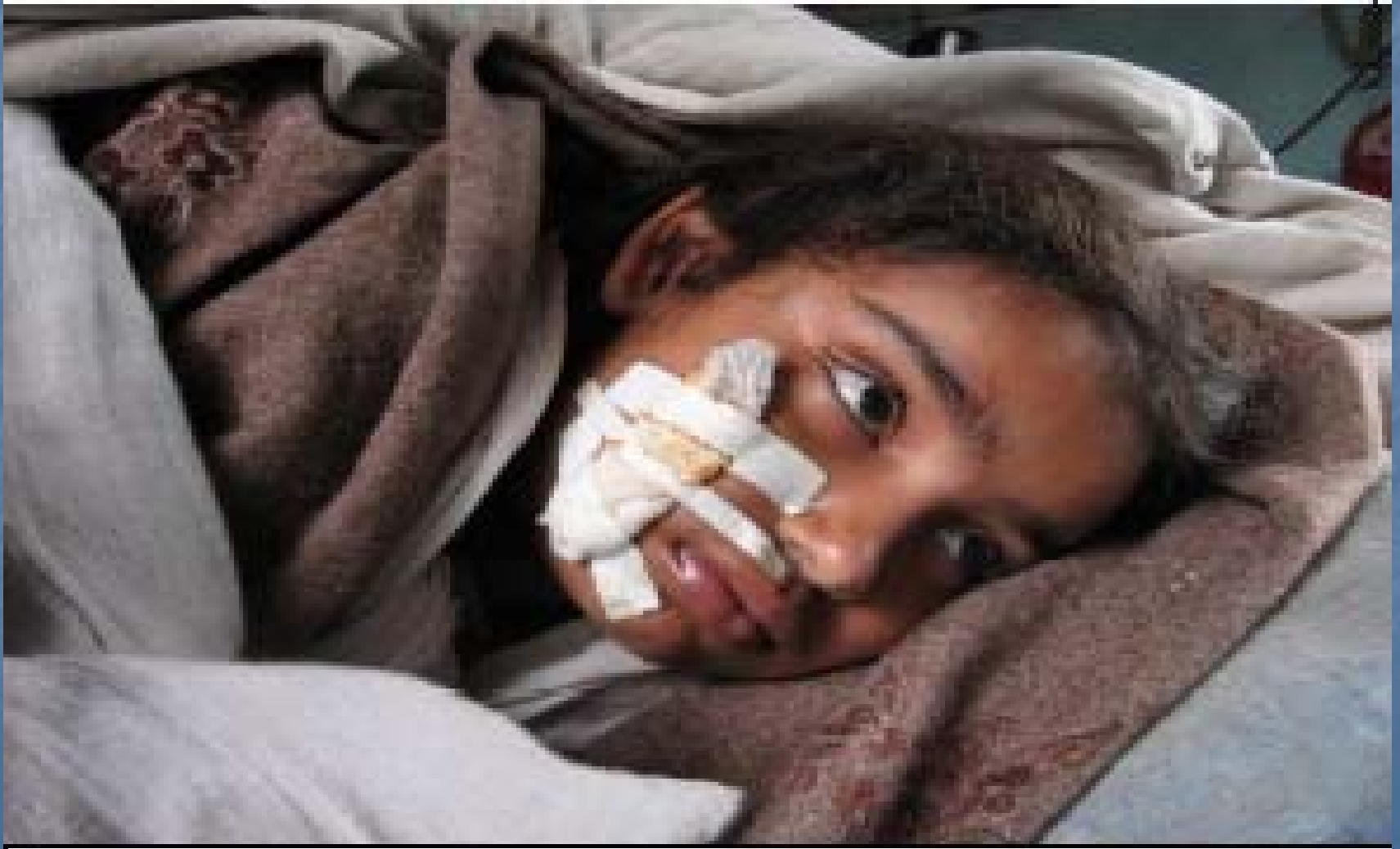It took some time before she felt the intolerable pain at the right side of her neck and chin.

She was horrified by the blood that started flooding the floor.

It was only then that she felt something was terribly wrong, and she screamed in panic.

It took a while for her guardians to understand that she was injured by a bullet fired by the policeman.

She was then taken to Nepalgunj Medical College Teaching Hospital in an ambulance.



At Nepalgunj Medical College:

- She was unconscious.
- The bullet injury on right mandible was obvious.
- X-ray showed the bullet was lodged very close to cervical vertebra.
- But, fortunately, no serious injury to the structures in the neck was evident.
- After resuscitation, she underwent open reduction and internal fixation of the fracture.

For further treatment, she was referred to the higher centre in Kathmandu.

That was not the end to the problem for the poor family that survived on the minimal wages her father earned working in a local sweet shop.

Actually the newer problem then began.....

He, father of the unfortunate girl,
visited the near and dear ones with a
hope....

...worrying about the unpredictable cost
of treatment, let alone the
unforeseen psychosocial
consequences to her daughter...

Not knowing what to do...

...he started seeking help from social organizations and people he hoped could help them out.

...when a social worker from an NGO, Jagrit Nepal, came into his troubled life...

...A flight was arranged from Nepalgunj to Kathmandu several days after the incident.

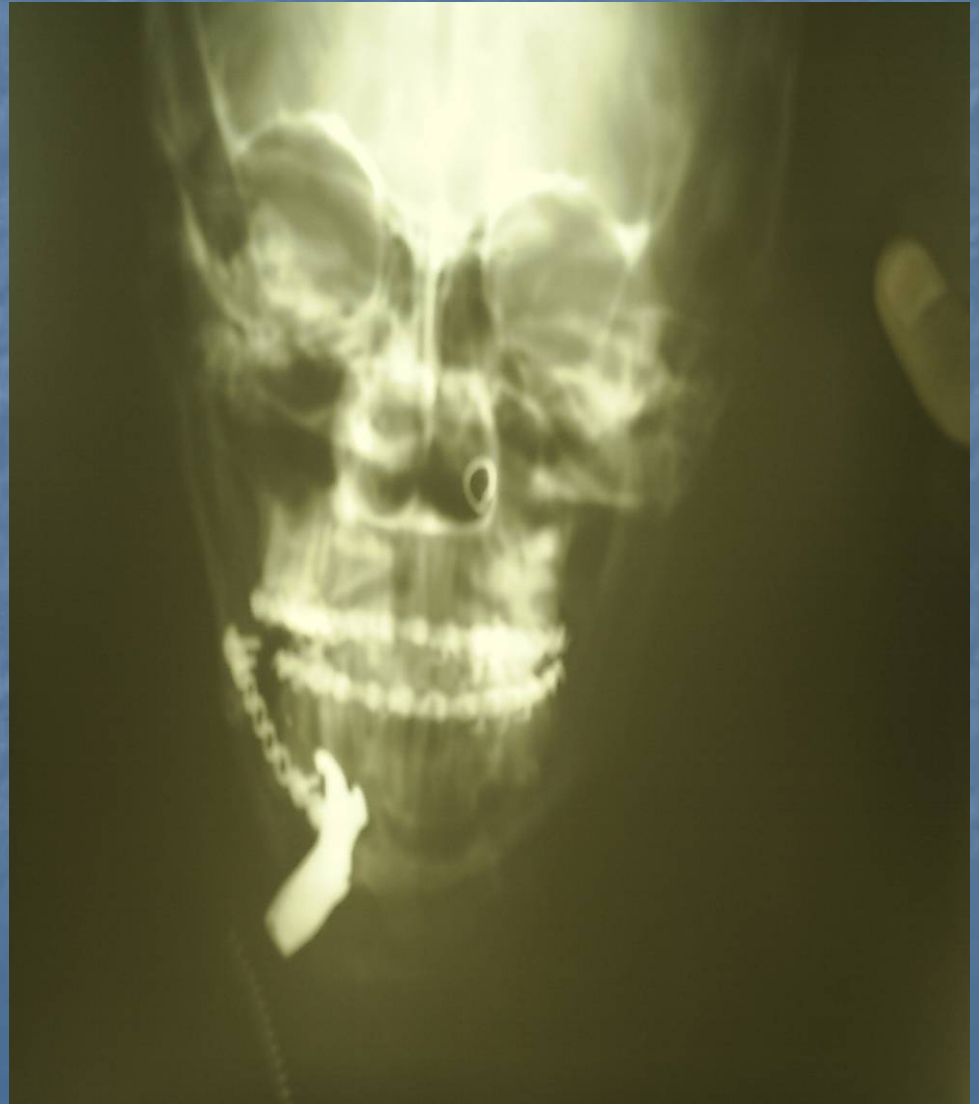...While her parents stayed with the other children at home.

At Kathmandu Model Hospital

- PSRN Dr. Saroj Dhital was the attending surgeon. He found her obviously in a state of post-trauma stress.
- She could not open her mouth because of immobilization of the jaws.
- The initial management of comminuted fracture of right mandible needed further management .
- The wound on the right side of neck was infected and discharging.
- X-ray showed a foreign body on the right neck region that looked like a bullet that had bent after encounter with the mandible and lodged somewhere very close to the cervical vertebra and major vessels.

X-RAY:

- **Metallic foreign body in right submandibular area, fracture of ramus of mandible with wire fixation.**



Fortunately....she was quite
stable by then.

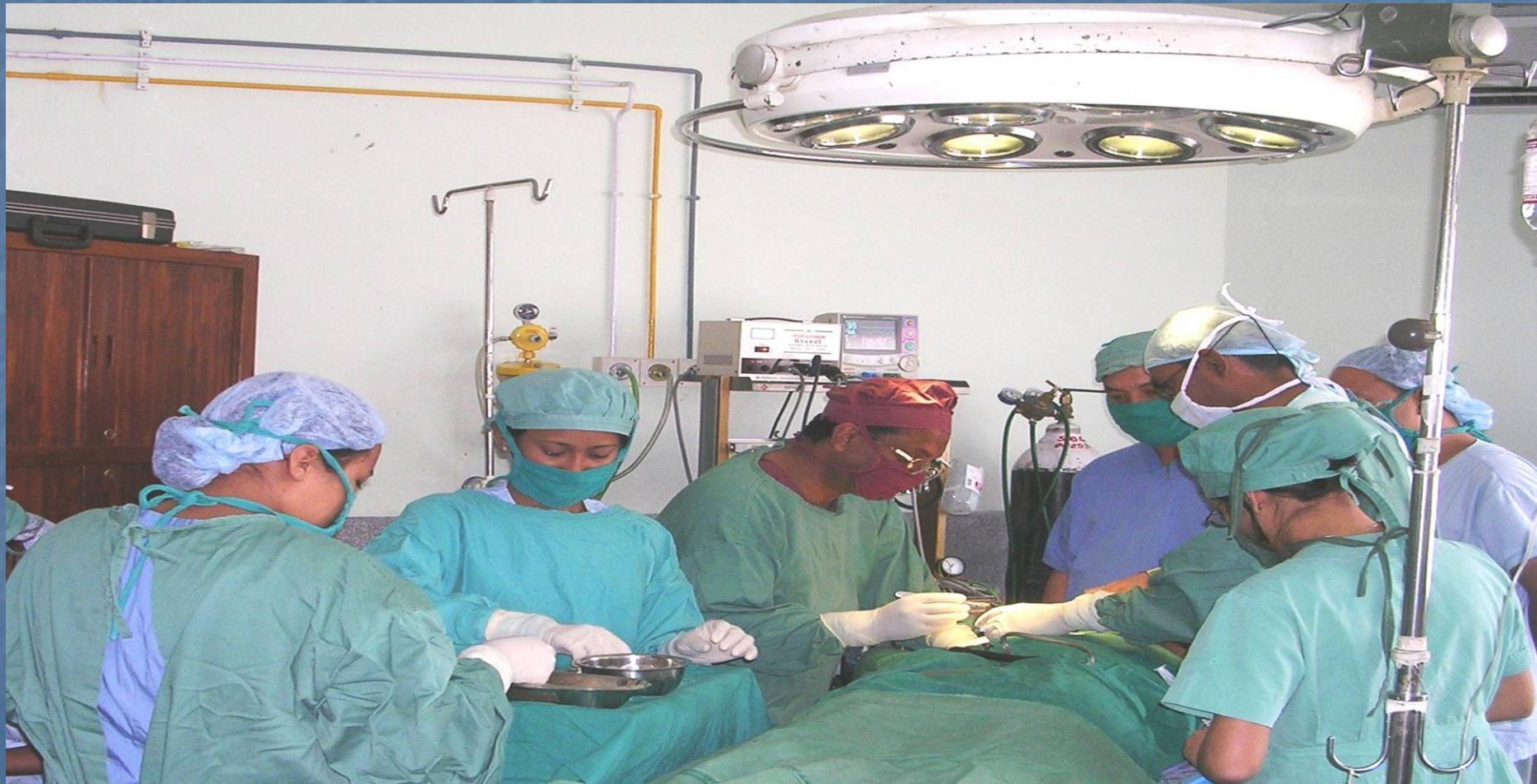CT Findings

- The bullet was seen a few centimeters away from the major vessels lateral and superior to thyroid cartilage.
- Laryngeal cartilages appeared normal.
- Fracture of the ramus of mandible was noted on the side with wire fixation.
- No abnormality seen in the parotid, masticator, pharyngeal mucosal spaces.
- No abnormality seen in cervical vertebrae.

It was

A narrow escape....

Exploration was done with removal of bullet



The operation note read...

- ... metallic bullet about 4cm with asymmetrically bent tip lodged 2cm away from the carotid...
- ... significant inflammatory reaction in surrounding area...
- ... abscess formation around bullet...
- ... no major vessels injured, carotid sheath not breached...
- ... few small fragments of bone inside the abscess cavity...



All this meant..

A really close save...

Even a small change in her position
would have meant ...

- Major injury to the vessels

Causing death

- Injury to the cervical spines

Causing paralysis

- The bullet could have entered the thorax

Causing severe damages...

It was unfortunate that she sustained the injury...

But she was fortunate that she survived just by chance.

BUT...

The psychological trauma she had will remain there forever...

The scar on her teenage mind will remain through her whole life...

The beautiful face of a lovely girl was made different for ever...

And...

Look at the expenses....

At Nepalgunj Medical College---Rs.44,000\ - (USD \$675)

At Kathmandu Model Hospital---Rs.29,000\ - (USD \$450)

Travel Expenses---Rs.31,200\ (airfare only)-(USD \$480)

Food And Accommodation--Rs.20,000\ - (USD \$305)

Rs. 124,200 or Nearly USD \$2000!

And much more that has not been included.....

The cost of one bullet injury :

Equivalent to 3.5 year's of her father's salary

- Would enable her to complete her education up to higher secondary level;
- Pay for 5 children to complete secondary level education;
- Allow her family member to have average Nepali meal for 4 years;
- Could establish one fully equipped sub-health post in her village;
- Would be enough for her to pursue medical education at the Institute of Medicine.

We can see that a 15 year old girl, normally at school, has undergone a serious physical trauma due to a bullet. The mental and psychological trauma associated with it is even more serious.

It may lead her to:

- drop out of school
- be discriminated against in her family and society
- have feelings of inferiority
- other siblings' care may be affected
- have a stigma, affecting her potential marriage
- have negative attitude towards policemen

.....and many more

Conclusion:

- Manashi is fortunate enough to receive treatment and remain alive, but she has passed through a horrible experience in her early life and the scars to her body *and also* her mind will remain for ever.
- Nothing in the world can compensate her life long sufferings.

And this was all caused by

- One bullet
- The inadvertently fired small arm used by the police: the protectors of human lives

And this was preventable

What can we do then... ?

- Primary prevention is the most appropriate way to deal with this grave problem causing massive casualties worldwide

If only

- We, the medical and public health personnel, share a common responsibility to work towards preventing small arms violence.

- Manashi, who we presented here, is not the only one.
- There are thousands of Manashi's here in Nepal...
- And millions in all nooks and corners of the world.
- Several similar stories were created over the span of our presentation.

Lets hope, let's pray and let's act,
so that Manashi's all over the world
can remain smiling.

***MAY PEACE PREVAIL
ON EARTH***

Acknowledgements:

- *Manashi Lakhel, the victim of the bullet*
- *Mr. Ramesh Lakhel, her father, for his consent*
- Dr. Saroj Dhital, Sr Vice President PSRN and surgeon who operated on Manashi, for guiding through preparation
- Dr. Bharat Pradhan and Dr. Bhim Kharel (Kathmandu Model Hospital)
- Dr. Khagendra Bikram Dahal, IMSR, IPPNW
- Mr. Vijaykant Karna and Mr. C.P. Singh, JAGRIT NEPAL
- PSR-Nepal, Student Chapter



